



ISSN 2278 – 0211 (Online)

Hepatoprotective Effect of Methanol Extract of *Parkia Biglobosa* Leaves on Acetaminophen-Induced Liver Damage in Wistar Rats

Fatima Ajuma Sule

Assistant Lecturer, Department of Biochemistry, Kogi State University Anyigba, Nigeria

Umoru Ogwu

Student, Department of Biochemistry, Kogi State University Anyigba, Nigeria

Wisdom Otaru Oniwon

Assistant Lecturer, Department of Biochemistry, Kogi State University Anyigba, Nigeria

Mercy Oguche

Assistant Lecturer, Department of Biochemistry, Kogi State University Anyigba, Nigeria

Rose Mafo Abaniwo

Assistant Lecturer, Department of Biochemistry, Kogi State University Anyigba, Nigeria

Isaac Eleojo Shaibu

Assistant Lecturer, Department of Biochemistry, Kogi State University Anyigba, Nigeria

Abstract:

This study was conducted to evaluate the in-vivo hepatoprotective effect of methanolic extract of *Parkia biglobosa* leaves. Hepatotoxicity was induced by oral administration of 500mg/kg Acetaminophen (Paracetamol). All drugs were administered as single daily dose by oral gavage for 14 days. Animals were grouped into five (5); Group I was control which received distilled water, group II received 500mg/kg of acetaminophen, group III received 500mg/kg of acetaminophen and treated orally with 140mg/kg of the standard drug silymarin group IV and V received acetaminophen and further treated with 75mg/kg and 200mg/kg of methanolic extract of *Parkia biglobosa* respectively. Phytochemical analysis of the extract was conducted using standard methods. The activity of the markers of hepatocellular injury was determined spectrophotometrically. Quantitatively, the extract has total phenols with the highest concentration (454.64 ± 0.51) mg/g. There was a significant increase ($p < 0.05$) in liver marker enzymes after hepatic injury AST (74.55 ± 2.16), ALT (32.16 ± 1.90) and ALP (24.95 ± 3.49). 75mg/kg and 200mg/kg of the extract significantly lowered ($p < 0.05$) the increased concentration of the marker enzymes after hepatic injury. However; at 75mg/kg of the extract, there was no significant decrease ($p > 0.05$) in AST levels. From the histological examination, the deteriorative effect induced on the liver tissue by acetaminophen was ameliorated after the administration of the extract. The protective activity of methanolic extract of *Parkia biglobosa* leaves is similar to the standard drug silymarin. Therefore, the extract has hepatoprotective property.

Keywords: Hepatoprotective, Acetaminophen, Silymarin, *Parkia biglobosa*

1. Introduction

The liver is an important organ in the body that is involved in detoxification, red blood cell decomposition, synthesis of plasma proteins, etc. Excessive consumption of paracetamol or paracetamol overdose can lead to hepatic damage caused by the synthesis of a reactive metabolite N-acetyl-pbenzoquinone imine (NAPQI) by Cytochrome P450 enzymes. The covalent binding of NAPQI, an oxidation product of paracetamol to sulphydryl groups of protein, induces oxidative stress which leads to cell necrosis and lipid peroxidation (Abeer *et al.*, 2016). Damage to the liver causes reduction of the antioxidant glutathione (GSH). This further causes necrosis of the cells and increased levels of biochemical markers present in the serum (AST, ALT, ALP, and bilirubin) (Mascolo *et al.*, 1998).

Various plant parts such as leaves, stem-bark, roots, fruits etc. is widely used in traditional medicine for the treatment of various ailments in humans and animals (Nweze *et al.*, 2004). *Parkia biglobosa* is a multiuse forage tree that belongs to the family Fabaceae and sub family mimosaceae (Sabit & Cobbina, 1992). *Parkia biglobosa* is predominantly known in Nigeria as African locust bean tree which is called *Igba* in Yoruba language, *Dorowa* in Hausa Language and *Origili* in Ibo (Gronhaug *et al.*, 2008; Tijani *et al.*, 2009). The stem bark is mixed with lemon for treatment of wounds and ulcers. In cote d' Ivoire and Nigeria, a bark infusion is used as a tonic for diarrhea and as an enema (Cruickshank *et al.*, 1973; Agunu *et al.*, 2005). A decoction of the stem bark is also used as a mouthwash to steam and relieve toothache as well as a bath for fever (Ajaiyeoba, 2002). The leaves are also used for burns and toothache as well as for sore eyes in Gambia (Banwo *et al.*, 2004).

This research was undertaken to investigate the hepatoprotective effect of methanolic extract of *Parkia biglobosa* leaves on acetaminophen-induced liver damage.

2. Materials and Methods

2.1. Plant Collection and Extract Preparation

Fresh leaves of *P. biglobosa* were collected in the premises of Kogi State University. The plant was identified and authenticated in the Biological Science Department, Kogi State University, Anyigba, where a voucher with specimen number RF-240:144 was kept. To obtain the methanol extract, pulverized leaves sample of *P. biglobosa* (500g) was weighed into a container, 1500ml of methanol was measured and added into the container and was allowed to stand for 24h. After 24h, it was filtered using vacuum filter into a conical flask. The filtrate was evaporated to dryness over a water bath. The extract was obtained and used for the analysis.

2.2. Chemicals

The ALT, AST and ALP kits used for the analysis were of analytical grade and products of RANDOX laboratory limited. Acetaminophen (PCM, 500mg). Silymarin (70mg; Micro Labs Limited, India)

2.3. Experimental Animals

Twenty-five (25) adult Wistar albino rats of both sexes were used for the study. The animals were randomly distributed into five groups with a group of five rats each. The animals were purchased from the animal facility Kogi state university. The animals were provided with regular vital feed and water *ad libitum*

2.4. Animal Grouping

- Group 1: Normal control (n=5, the animals were orally administered distilled water only for 14days)
- Group 2: Hepatotoxic control (n=5, the animals were orally administered 500mg/kg Acetaminophen for 14days)
- Group 3: Treatment control (n=5, the animals were orally administered 500mg/kg Acetaminophen and 140mg/kg Silymarin concurrently for 14days)
- Group 4: Treatment group (n=5, the animals were orally administered 500mg/kg Acetaminophen and 75mg/kg of the plant extract concurrently for 14days)
- Group 5: Treatment group (n=5, the animals were orally administered 500mg/kg Acetaminophen and 200mg/kg of the plant extract concurrently for 14days)

3. Analytical Procedure

3.1. Hepatotoxic Analysis

Hepatotoxicity was induced by the method described by Meraiyebu *et al.* (2013) with slight modifications (14 days oral administration). After 14 days of oral administration, the animals were sacrificed by cervical dislocation. The liver was collected and weighed. The liver samples were homogenized and centrifuged at 3000rpm for 10min.

3.2. Liver Marker Enzymes

The serum was collected to evaluate some liver enzymes activity such as Aspartate transaminase (AST), Alkaline phosphatase (ALP) and Alanine transaminase (ALT) using standard RANDOX kits.

3.3. Qualitative Phytochemical Analysis

Phytochemical screening was carried out according to standard methods (Harborne, 1998; Trease and Evans, 2002).

3.4. Histopathological Study

Small pieces of liver tissues in each group were collected in 10% neutral buffered formalin for proper fixation. These tissues were processed and embedded in paraffin wax. Sections of 5-6µm in thickness were cut and stained with hematoxylin and eosin (H & E). These sections were examined for histopathological changes and photographed (Bancroft *et al.*, 1996).

3.5. Statistical Analysis

The results are expressed as Mean \pm S.E.M. The significant differences ($P < 0.05$) among means were analyzed using one way ANOVA.

4. Results and Discussion

4.1. Extraction Yield of Plant Material

The methanolic extract of *Parkia biglobosa* leaves has a percentage yield of 18.20%. This result is comparable to that obtained by Solomon *et al.* (2018) in which a percentage extract yield of 17.43% was obtained.

4.2. Phytochemical Constituents of the Plant

Chemical Compounds	Methanol Extract
Alkaloids	+
Flavonoids	+
Cardiac glycosides	+
Saponins	+
Tannins	+
Total phenol	+

Table 1: Qualitative Phytochemical Screening of Methanolic Extract of *Parkia Biglobosa* Leaves
Key: + (Present)

Chemical Compounds	Concentration (mg/g)
Alkaloids	4.20 ± 0.02
Flavonoids	88.33 ± 0.21
Cardiac glycosides	0.38 ± 0.11
Saponins	5.46 ± 0.07
Tannins	8.64 ± 0.30
Total phenol	454.64 ± 0.51

Table 2: Quantitative Phytochemical Analysis of Methanolic Extract of *Parkia Biglobosa* Leaves
Results Are Expressed as Mean ± SEM (N=3)

The phytochemical constituents of methanolic extract of *Parkia biglobosa* leaves indicates the presence of alkaloids, flavonoids, cardiac glycosides, saponins, tannins and total phenol. The phytochemicals total phenols and flavonoids were in highest concentrations of 454.64±0.51mg/g and 88.33±0.21mg/g respectively. This result is in agreement with the report by Solomon *et al.* (2018) where similar phytochemical constituents were reported in the methanol extract of *Parkia biglobosa* leaves. However; Ajaiyeoba (2002) reported the presence of tannins in the ethanol and aqueous extract of *Parkia biglobosa* leaves.

Some medicinal plants are known to contain antioxidants which have been reported to Protect against free radical oxidative damage and prevent diseases, aging and cancer (Meraiyebu *et al.*, 2013). The high concentrations of total phenol and flavonoids may be responsible for the hepatoprotective effect of the extract by protecting the liver against the reactive metabolite N-acetyl-pbenzoquinoneimine (NAPQI) formed due to paracetamol overdose. High level of a plant's phenolic constituent contributes to its antioxidant activity (Dash *et al.*, 2007). Flavonoids have been also shown to possess antioxidant and anti-inflammatory activities (Manga *et al.*, 2004).

4.3. Hepatoprotective Effect of the Plant

Groups	Extract Administration	Aspartate Transaminase (IU/L)	Alanine Transaminase (IU/L)	Alkaline Phosphatase (IU/L)
I	Distilled water	51.17 ± 7.01	27.71 ± 1.91	19.27 ± 1.85
II	500mg/kg Acetaminophen	74.55 ± 8.86 ^b	32.16 ± 1.90 ^b	24.95 ± 3.49 ^b
III	500mg/kg Acetaminophen + 140mg/kg Silymarin	62.16 ± 4.84 ^{ab}	20.75 ± 2.28 ^{b,ab}	21.32 ± 5.97 ^{b,ab}
IV	500mg/kg Acetaminophen + 75mg/kg MEPBL	73.08 ± 1.00 ^b	26.08 ± 1.23 ^{ab}	23.89 ± 3.01 ^{b,ab}
V	500mg/kg + Acetaminophen 200mg/kg MEPBL	60.55 ± 2.10 ^{ab}	27.68 ± 2.57 ^{ab}	22.45 ± 3.60 ^{b,ab}

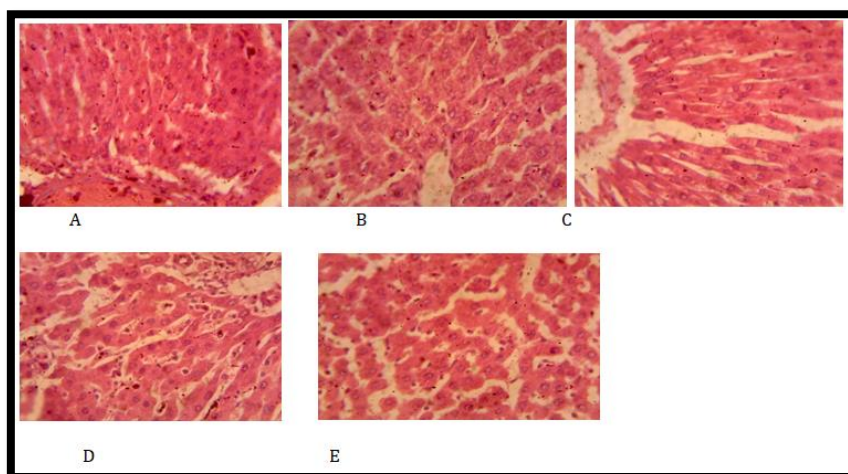
Table 3: Effect of Methanolic Extract of *Parkia Biglobosa* Leaves on Biochemical Markers of Liver Function after Two Weeks of Oral Administration
Mepbl – Methanolic Extract of *Parkia Biglobosa* Leaves

Each value is mean ± S.E.M for five rats in each group. ^b indicates values that are significantly different when compared with the control group at (p<0.05), ^{ab} indicates values that are significantly different when compared with the induced group at (p<0.05).

The activities of ALT and AST have been used as a good marker for the assessment of liver function. These enzymes are released from damaged hepatocytes and their activity in plasma is increased. The activity of these enzymes is therefore used as a marker of hepatocellular damage (Debray *et al.*, 2011).

There was a significant increase in liver marker enzymes (ALT, AST and ALP) after induction of hepatic injury by paracetamol. This result is in agreement with previous studies which reported that excessive consumption/overdose of paracetamol could lead to hepatotoxicity (Gini & Muraleedhara, 2010; Meraiyebu *et al.*, 2013). Treatment with the methanolic extract of *Parkia biglobosa* leaves significantly lowered the increased levels of the liver marker enzymes (ALT and AST) which were indicative of hepatic injury. Increase in biliary pressure and cholestasis results in elevated synthesis of serum ALP by the bile canaliculi cells. (Gini & Muraleedhara, 2010). The hepatoprotective effect of the extract is comparable to that of the standard drug silymarin. This is based on the significant alleviation of the paracetamol-induced elevation of liver marker enzymes. The effect of the extract agrees with the view that; upon healing of the hepatic parenchyma and regeneration of hepatocytes, the increased levels of the serum transaminases will return to normal (Ahmed & Khater, 2001; Pawlikowska *et al.*, 2007)

4.4. Histopathological Study of Rat Liver



Figures 1: Photomicrograph of the Rat Liver (H&E Stain) under Low Power (X400)

- Normal control group
- Acetaminophen-hepatotoxic group
- Silymarin (140mg/kg) + Acetaminophen 500mg/kg
- *P.biglobosa* (75mg/kg) + Acetaminophen 500mg/kg
- *P.biglobosa* (200mg/kg) + Acetaminophen 500mg/kg

In this study, the result of the histopathological analysis further confirmed the hepatoprotective activity of the plant extract. The rats in the control group (A) show normal hepatic cells with no sign of necrosis nor inflammation. The acetaminophen hepatotoxic group (B) shows inflammation, necrosis of the hepatic cell and disappearance of the nuclei. This could be as a result of oxidative stress and release of free radicals induced by acetaminophen overdose. However, treatment with the standard drug silymarin (C) shows a near normal hepatic structure. Treatment with 75mg/kg and 200mg/kg of *P.biglobosa* extract (D & E) shows a mild inflammation and reparative process of the hepatic cells with the appearance of the nuclei.

5. Conclusion

Based on our research, the methanolic extract of *Parkia biglobosa* leaves possess hepatoprotective effect against acetaminophen-induced liver damage. This hepatoprotective effect may be attributed partly to the phytochemical composition of the *Parkia biglobosa* leaves.

6. References

- Ajaiyeoba, E. (2002). Phytochemical and antibacterial properties of *Parkia biglobosa* and *P.bicolor* leaf extracts. *African Journal of Biomedical Research*. 5(1), 125-129
- Abeer ,H., Hibah, M.A, Jihan, M.B., Amanyil, K.I. & Seham, E.A. (2016). Evaluation of hepatoprotective activity of *Adansonia digitata* extract on acetaminophen induced hepatotoxicity in rats. *Evidence-based complementary and alternative medicine*. 1-7
- Agunu, A., Yusuf, S., Andrew, G.O., Zezi, A.U. & Abdulrahman, E.M. (2005). Evaluation of five medicinal plants used in diarrhea treatment in Nigeria. *Journal of Ethnopharmacology*. 101, 27-30
- Ahmed, M.B. & Khater, M.R. (2001). Evaluation of the protective potential of Ambrosia maritime extract on acetaminophen induced liver damage. *Journal of Ethnopharmacology*; 75,169-174
- Bancroft, D., Steven, A. & Turner, R. (1996). *Theory and practice histological techniques*. 4th ed London: churchil livingstone
- Banwo, G. O., Abdullahi, I.,& Duguryil, M. (2004). The Antimicrobial Activity of the Stem Bark of *Parkia clappertoniana* keay family Leguminosae Against Selected Microorganisms. *Nigerian Journal of Pharmaceutical Research*, 3(1),16-22.

- vii. Cruickshank, R., Duguid, J.P., Marmoin, B.P. & Swain, R. H. (1973). *Medical Microbiology* 12th Ed. Edingburgh: ELBS
- viii. Dash, D.K., Yeligar, V.C. & Nayak, S.S. (2007). Evaluation of hepatoprotective and antioxidant activity of *Ichnocarpus frutescens* (Linn) on paracetamol induced hepatotoxicity in rats. *Tropical Journal of Pharmaceutical Research*, 6(3), 755-765
- ix. Debray, D. D., Houwen, R., Strandvik, B. & Colombo, C. (2011). Best practice guidance for the diagnosis and management of cystic fibrosis associated liver disease. *Journal of Cystic Fibrosis*, 10, 29-S36
- x. Gini, C.K & Muraleedhara, G.K. (2010). Hepatoprotective effect of *Spirulina lonar* on paracetamol induced liver damage in rats. *Asian Journal of Experimental Biological Sciences*, 1, 614-623
- xi. Grounhaug, T.E., Glaeserud, S., Skogsrud, M., Ballo, N., Bah, S., Diallo, D. & Paulsen, B. (2008). Ethnopharmacological survey of six medicinal plants from Mali, West Africa. *Journal of Ethnobiology and Ethnomedicine*, 4(26), 1-10
- xii. Harborne, J.B. (1998). Nitrogen compound in phytochemical method, *A guide to modern techniques of plant analysis*. 3rd edition, London: Chapman & Hall
- xiii. Manga, H.M., Brkic, D. Marie, D.E.P & Quetin-Leclercq J (2004). In vivo anti-inflammatory activity of *Alchonear cordifolia*. *Journal of Ethnopharmacology*, 92, 209-214
- xiv. Mascolo, N., Sharma, R., Jain, S.C. & Capasso, F. (1998). Ethnopharmacology of *Calotropis procera* flowers. *Journal of Ethnopharmacology*, 22, 211-244
- xv. Meraiyebu, A., Olaniyan, O., Abutu, S., Dare, J. & Atsukwei, D. (2013). Hepatoprotective effect of *Parkia biglobosa* stem bark methanolic extract on paracetamol induced liver damage in wistar rats. *American Journal of Biomedical and Life Sciences*, 1(4), 75-78
- xvi. Nweze, E. L., Okafor J. L. & Njoku O. (2004). Antimicrobial Activities of Methanolic Extracts of *Trume guineensis* (Schumm and thom) and *Morinda lucinda* Benth Used in Nigeria Traditional Medicinal Practice. *Journal of Biological Research and Biotechnology*, 2(1), 34-46.
- xvii. Pawlikowska-pawelga, B., Gruszecki, W.I., Misiak, L., Paduch, R., Piersiak, T. & Zarzyka, B. (2007). Modification of membranes by quercetin, a naturally occurring flavonoid via its incorporation in the polar head group. *Biochimica et Biophysica Acta*, 1768, 2195-2204
- xviii. Sabiti, E.N. & Cobbina, J. (1992). *Parkia biglobosa*. A potential multipurpose fodder tree legume in West Africa. *International Tree Crops Journal*, 7, 113-139
- xix. Solomon, J., Mustapha, B.A., Yaqub, A.G., Mohammed, Y.Z., Iliya, D.K., Isa, A. G. & Iliya, I. (2018). Phytochemical and antimicrobial profile analysis of *Parkia biglobosa* against methicillin-resistant *Staphylococcus aureus*. *Journal of Advanced Veterinary and Animal Research*, 5(2), 173-181
- xx. Tijani, A.Y., Okhale, S.E., Salawu, T.A., Onigbanjo, H.O., Obianodo, L.A., Akingbasote, J.A., Salawu, O.A., Okogun, J.I., Kunle, F.O. and Emeje, M. (2009). Antidiarrhoeal and antibacterial properties of crude aqueous stem bark extract and fractions of *Parkia biglobosa* (Jacq). *African Journal of Pharmacy and Pharmacology*, 3, 347 - 353
- xxi. Trease, G.E. & Evans, W.C. (1989). *Phytochemistry*, 13th edition, London: Bailere Tindall Ltd