



ISSN 2278 – 0211 (Online)

Post Hatch Development of Chromaffin Tissue in the Adrenal Gland of Kuttanad Ducks (*Anas Platyrhynchos Domesticus*)

Fathima R.

Teaching Assistant, Department of Veterinary Anatomy and Histology,
College of Veterinary and Animal Sciences, Pookode, Wayanad, Kerala, India

K. M. Lucy

Associate Professor and Head, Department of Veterinary Anatomy and Histology,
College of Veterinary and Animal Sciences, Pookode, Wayanad, Kerala, India

Abstract:

The study was conducted to understand developmental pattern of chromaffin tissue in the adrenal gland of Kuttanad ducks (*Anas platyrhynchos domesticus*) during post hatch period. In day-old birds, chromaffin islets were irregular in shape and consisted of lightly and darkly stained cells. Among the two types of chromaffin cells, the darker norepinephrine cells predominated over the light epinephrine cells in day-old birds. By six weeks, chromaffin tissue became highly active with granular cytoplasm. Large number of small and large ganglion cells appeared at this stage and were found associated with the chromaffin tissue. At 10 weeks, most of the chromaffin tissue was seen concentrating towards the central zone of the gland. At 12 weeks, the chromaffin cells showed numerous granules and most of the islets were surrounded by venous sinuses. Nuclear diameter of chromaffin cells was greater than those of the interrenal cells in all the age groups. Many cells in the chromaffin tissue showed two to three nucleoli in the nucleus. At 18 weeks, chromaffin cells were seen trapped in the capsule as solitary cells and as islets. Another feature was that the chromaffin tissue started aggregating near the sinusoids. Large number of chromaffin islets was distributed in the centre of the gland and crowded around the venous sinuses. In the adult birds (24 weeks), the most important peculiarity noted was the arrangement of chromaffin tissue. They formed columns of cells in between the inter-renal cords and each column extended from the capsule and reached upto the central zone.

Keywords: Chromaffin tissue, post hatch development, adrenal, Kuttanad ducks

1. Introduction

Unlike that of mammals, a distinct cortex and medulla is absent in avian adrenal gland. Instead, it shows two morphologically and physiologically different endocrine regions, the interrenal (cortical) tissue and chromaffin cells (medullary tissue). Medullar cells are named chromaffin cells as they possess higher affinity to the chromium salts and they turn brownish upon treatment with chromium salts. Chromaffin cells are mainly of two types viz., the norepinephrine cells and epinephrine cells. Knowledge in the developmental anatomy of the avian adrenal gland will be helpful for understanding the functional correlates of the organ in the species. Although research has been conducted on the chromaffin tissue of domestic fowl and Japanese quail, information regarding the normal structure and post hatch developmental pattern of the adrenal gland in duck is scanty. Kuttanad ducks are reared extensively in Kerala and are well adapted to the climatic conditions of the state. Therefore, comprehensive study on the post hatch development of the adrenal gland in this species seems to be a relevant area of research.

2. Materials and Methods

Present study was carried out in 78 female Kuttanad ducks of different age groups, ranging from day-old to 24 weeks. The adrenal glands were collected from six birds in each age group at fortnightly intervals up to 24 weeks. After recording the gross features, the materials were fixed in the fixatives such as 10 per cent neutral buffered formalin, Bouin's fluid and Formol-Dichromate at pH 4.0-4.2 (Wood, 1963). The materials were then processed for paraffin embedding and sections of 5 µm thickness were taken for histological studies. Haematoxylin and Eosin (H&E) staining technique and Wood's technique for medullary catecholamine cells (Wood, 1963) were done to differentiate the cell types of chromaffin tissue.

3. Results and Discussion

In day-old birds, chromaffin cells were found to be basophilic than the inter-renal tissue. The chromaffin islets were irregular in shape including elongated, oval and triangular masses (Fig. 1) as noticed by Basha *et al.* (2009) in day-old Japanese quail and Tang *et al.* (2009) in ostrich chicks. At two weeks, the chromaffin islets were small and globular in cross section (Fig. 2). Chromaffin tissue consisted of lightly and darkly stained polygonal cells. Similar observations were made in ostrich chicks by Tang *et al.* (2009).

The darker cells possessed larger nuclei than those of the lighter cells in all the age groups. Among the two types of chromaffin cells, the darker cells predominated over the light cells in day-old birds. By Woods staining technique, large cells could be identified as the epinephrine or adrenalin cells and the small cells, the norepinephrine or noradrenalin cells. Ghosh (1973) reported that unlike in mammals, avian adrenal medullary tissue except passeriformes showed more norepinephrine cells than epinephrine cells.

By six weeks, both the inter-renal tissue and chromaffin tissue became highly active with granular cytoplasm. Rajendranath *et al.* (2012) reported the presence of numerous basophilic chromaffin granules in the cytoplasm of medullary cells in adult emu. Large number of small and large ganglion cells appeared at this stage and were associated with the chromaffin tissue.

At 10 weeks, most of the chromaffin tissue was seen concentrating towards the central zone of the gland. Among the chromaffin cells, norepinephrine cells predominated at this stage. The result was in accordance with the findings of Basha *et al.* (2004) in immature (2-6 weeks) Japanese quail. At 12 weeks, the chromaffin cells showed numerous granules. Most of the chromaffin islets were surrounded by venous sinuses. Nuclear diameter of chromaffin cells was greater than those of the inter-renal cells in all the age groups. Many cells in the chromaffin tissue showed two to three nucleoli in the nucleus. The same nuclear features were observed by Sivaram (1965) in domestic fowl and Rajendranath *et al.* (2012) in emu. The variations in the content of medullary cells particularly in the amount of basophilic secretory granules and the appearance of nuclei could be related to the physiological activity of the cells as described Payne (1955) in domestic fowl.

At 16 weeks of age, the birds started laying eggs and among the chromaffin cells, majority was norepinephrine cells. At 18 weeks, chromaffin cells were seen trapped in the capsule of the adrenal gland as solitary cells and as islets (Fig. 3). Another feature was that the chromaffin tissue started aggregating near the sinusoids (Fig. 4). Similar observations were also documented by Basha *et al.* (2004) in adult Japanese quail.

Adrenal gland of 20 weeks-old birds also showed the presence of chromaffin tissue in the capsule as well as in the subcapsular zone. The islets of chromaffin tissue started bridging together (Fig. 5). Large number of chromaffin islets was distributed in the centre of the gland and crowded around the venous sinuses. The same pattern of distribution was noted by Basha *et al.* (2004) in Japanese quail. At 22 weeks, chromaffin tissue could be located outside the capsule of the organ (Fig. 6). Freedman (1968) reported the presence of nerve cell bodies and chromaffin cells in the pericapsular sheath in the adrenal gland of adult chicken. Central zone showed large number of irregular sinusoids.

In the adult birds (24 weeks), the most important peculiarity noted was the arrangement of chromaffin tissue. They formed columns of cells in between the inter-renal cords (Fig. 7). Each column extended from the capsule and reached upto the central zone. The cell thickness of these cords also varied from single cell to several cells. Large irregular islets were also identified. Even though the relative proportion of chromaffin tissue was reduced; overall amount of it in the gland seems to be increased. The islets were replaced by elongated columns and they were often connected by narrow bridges. Considerable amount of chromaffin tissue was found on the surface of the gland. These results are in accordance with the findings of Hartman and Albertin (1951) in birds.

The overall pattern of chromaffin tissue distribution in the adrenal gland of Kuttanad duck during the post hatch period was as follows. When there was relatively small amount of chromaffin tissue, it was scattered through the inter-renal tissue in the form of small bodies or islets of various sizes in all the zones. As age advanced, the chromaffin tissue was more aggregated towards the central portion of the gland. Later, when the amount of chromaffin tissue increased, the islets became larger, often elongated and sometimes connected with one another by thin bridges. With large proportion of the chromaffin tissue, much of it reached the surface of the gland.

4. References

1. Basha, S. H., Kannan, T. A. & Ramesh, G. (2009). Age related changes of the adrenal gland in Japanese quail (*Coturnixcoturnix japonica*), Tamilnadu Journal of Veterinary and Animal Sciences, 5: 198-202.
2. Basha, S. H., Vijayaragavan, C. & Ramesh, G. (2004). Light and electron microscopic studies on the interrenal tissue of the adrenal gland in Japanese quail (*Coturnixcoturnix japonica*). Indian Journal of Animal Sciences, 74: 1021-1023.
3. Freedman, S. L. (1968). The innervation of the suprarenal glands of the fowl (*Gallus domesticus*). Acta Anatomica, 69: 18.
4. Ghosh, A. (1973). Histophysiology of the avian adrenal medulla. Proceedings of 60th Indian Science Congress, Part II, p.1
5. Hartman, F. A. & Albertin, R. H. (1951). A preliminary study of the avian adrenal. The Auk, 68: 202-209.
6. Payne, F. (1955). Adrenal ganglia and medullary cells in hypophysectomised and ageing fowl. Journal of Experimental Zoology, 128: 259-272.
7. Rajendranath, N., Babu, A. P., Ramayya, P. J., Patki, H. S. & Rao, T. S. C. (2012). Histology of the adrenal gland of emu (*Dromaius novae hollandiae*). Indian Veterinary Journal, 89: 56-57.
8. Sivaram, S. (1965). Structure and development of adrenal gland of *Gallus domesticus*. Canadian Journal of Zoology, 43: 1021-1031.
9. Tang, L. Peng, K.M., Wang, J. X., Luo, H. Q., Cheng, J. Y., Zhang, G. Y., Sun, Y.F., Liu, H. Z. & Song, H. (2009). The morphological study on the adrenal gland of African ostrich chicks. Tissue and Cell, 41: 231-238.

10. Wood, J. G. (1963). Identification of and observations of epinephrine and norepinephrine containing cells in the adrenal medulla. American Journal of Anatomy, 112: 285-303

1. Capsule 2. Parenchyma

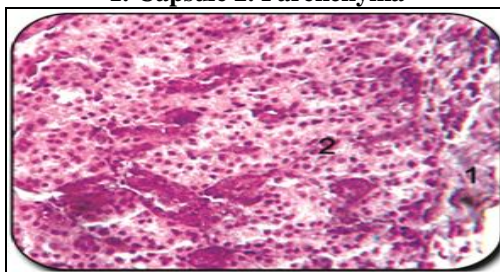


Figure 1: C. S. of adrenal gland (day-old). H & E x 400

1. Interrenal tissue 2. Globular chromaffin islets 3. Venous sinuses

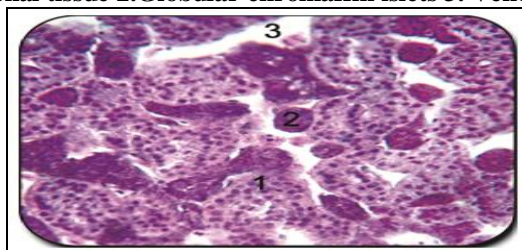


Figure 2: C. S. of adrenal gland showing globular chromaffin islets (2 weeks). H & E x 400

1. Capsule 2. Chromaffin tissue 3. Interrenal tissue

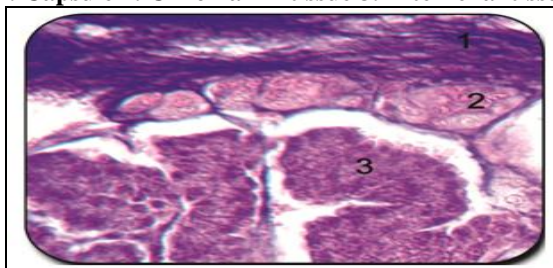


Figure 3: C. S. of adrenal gland showing chromaffin tissue within the capsule (18 weeks). Wood's technique x 400

1. Chromaffin tissue 2. Sinusoids 3. Interrenal tissue

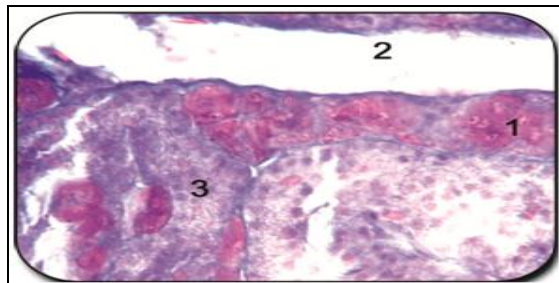


Figure 4: C. S. of adrenal gland showing accumulation of chromaffin tissue near sinusoids (18 weeks). Wood's technique x 400

1. Nerve bundle in pericapsular area 2. Capsule 3. Chromaffin tissue 4. Interrenal tissue

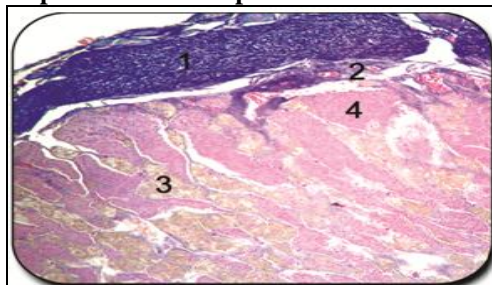


Figure 5: C. S. of adrenal gland showing distribution of chromaffin tissue (20 weeks). Wood's technique x 400

1. Chromaffin cells 2. Blood vessels 3. Parenchyma of gland

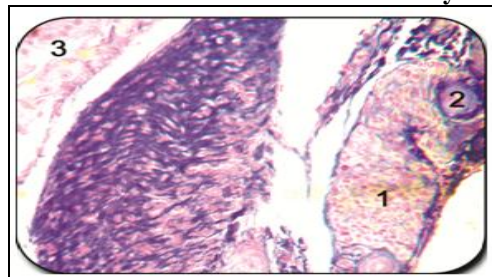


Figure 6: C. S. of adrenal gland showing chromaffin tissue outside the capsule (22 weeks). Wood's technique x 400

1. Chromaffin tissue columns 2. Interrenal cords

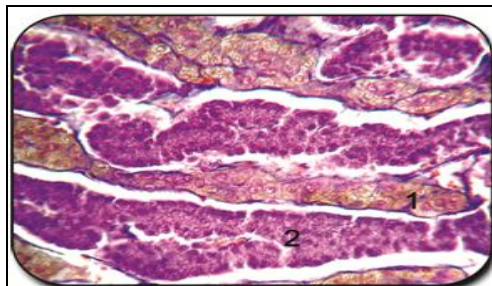


Figure 7: C. S. of adrenal gland showing column of chromaffin tissue between interrenal tissues (24 weeks). Wood's technique x 400